Vitrectomy for Persistent Diffuse Diabetic Macular Edema

ULRIKE STOLBA, MD, SUSANNE BINDER, MD, DIEGO GRUBER, ILSE KREBS, MD, TINA AGGERMANN, MD, AND BEATRIX NEUMAIER, MD

• PURPOSE: To evaluate the potential benefit of vitrectomy in eyes with persistent diffuse macular edema.

• DESIGN: Prospective randomized comparative clinical trial.

• METHODS: Eyes with diffuse diabetic macular edema for 6 to 18 months, an attached posterior hyaloid, and grid laser photocoagulation performed at least 4 months before were included. Patients were randomized either to a vitrectomy group or to a control group. MAIN OUTCOME MEASURES: Evaluations of Early Treatment Diabetic Retinopathy Study (ETDRS) visual acuity, reading vision, and retinal thickness were carried out at baseline and 1, 3, and 6 months after enrollment.

• RESULTS: Fifty-six eyes (100%) were enrolled in this study. Twenty-five eyes (44.6%) were randomized into Gr I (vitrectomy group) and 31 eyes (55.4%) into Gr II (controls). Both groups were comparable in mean age (62.7 years and 63.9 years) and distribution of gender (one third male, two thirds female).

ETDRS visual acuity showed a statistical significance in favor of Gr I at all time points (P = .035 to .005 Fisher's exact test). With Jaeger charts a significance for Gr I was found only at the 6-month examination (P = .01). With optical coherence tomography, the different behavior of retinal thickness changes in both groups during follow-up was statistically significant; P values were <.0001 for month 1, 3, and 6, preferring Gr I.

• CONCLUSIONS: We provide evidence that vitrectomy with internal limiting membrane peeling is superior to observation alone in eyes with persistent diffuse diabetic macular edema for 6 to 18 months. Longer follow-up periods and larger series might be needed to confirm these results and gain additional information. (Am J Ophthalmol 2005;140:295–301. © 2005 by Elsevier Inc. All rights reserved.)

Accepted for publication Mar 21, 2005.

From the Department of Ophthalmology, Rudolf Foundation Clinic (U.S., S.B., I.K., B.N.); The Ludwig Boltzmann Institute of Retinology and Biomicroscopical Laser Surgery (U.S., S.B., I.K., T.A., B.N.); and Department of Medical Statistics, Medical University of Vienna (D.G.), Vienna, Austria.

Inquiries to Ulrike Stolba, MD, Department of Ophthalmology, Rudolf Foundation Clinic, Juchgasse 25, A 1030 Vienna, Austria; fax: 00431 71165 4609; e-mail: ulrike.stolba@wienkav.at

MACULAR EDEMA IS A COMMON CAUSE OF VISUAL impairment in patients with diabetic retinopathy, which occurs in approximately 29% of diabetic patients with at least 20 years duration of the disease.[1] Focal or grid laser photocoagulation has been standard treatment for clinically significant macular edema,[2] reducing the risk of moderate visual loss by 50%. However, the prognosis after laser treatment for diffuse edema was worse than for focal edema.[3–6]

The pathogenesis of diffuse edema is more complex than that of other forms of macular edema and includes poorly demarcated leakage from abnormal retinal capillaries and microaneurysms.[7] Besides the influence of the duration of diabetes mellitus, insulin dependence, HbA_{1c}, proteinuria, hypertension, and panretinal laser photocoagulation,[8–10] the role of the posterior hyaloid has become increasingly recognized. Nasrallah and associates[11] observed in 1988 a lower incidence of posterior vitreous detachment in eyes with diabetic macular edema compared with eyes without edema. Lewis and colleagues[12] described the first encouraging results after vitrectomy in diabetic eyes with macular traction in 1992. In the following years, retrospective studies of single case series have shown the advantage of vitrectomy and removal of the posterior hyaloid on morphologic and functional results.[13–22] In addition, spontaneous resolution of edema in 55% of eyes with posterior vitreous separation, compared with 25% of eyes with or without incomplete posterior vitreous detachment, was observed by Hikichi and associates in 1997.[23]

To evaluate prospectively a potential benefit of vitrectomy in eyes with persistent diffuse diabetic macular edema compared with a control group not undergoing operation, the following study was carried out. The efficacy of vitrectomy for diabetic macular edema should be assessed by both functional and morphologic outcomes.

METHODS

THIS WAS A PROSPECTIVE RANDOMIZED COMPARATIVE clinical trial. Patients were included when they fulfilled the following criteria: history of diffuse macular edema for

0002-9394/05/$30.00
doi:10.1016/j.ajo.2005.03.045

TABLE 1. Results of Early Treatment of Diabetic Retinopathy Study (ETDRS) Visual Acuity in Eyes Following Vitrectomy for Diffuse Diabetic Macular Edema (OP I) Compared With an Unoperated Control Group (CO II)*

Time (mo after enrollment)	Group	Worsened > 10 letters	No Change	Improved > 10 letters	*P* value for Chi-Square	Fisher's Exact Test *P* value (2-Tail)
1	OP I	5 (20%)	7 (28%)	13 (52%)	.032161	.035381
	CO II	8 (25.8%)	17 (54.8%)	6 (19.4%)		
3	OP I	4 (16%)	11 (44%)	10 (40%)	.036517	.035788
	CO II	12 (38.7%)	15 (48.4%)	4 (12.9%)		
6	OP I	4 (16%)	8 (32%)	13 (52%)	.004880	.005814
	CO II	13 (41.9%)	14 (45.2%)	4 (12.9%)		

*The results are listed in absolute numbers of patients and percentages due to changes of more than 10 letters in both directions or unchanged values. Statistical evaluation (chi- square and Fisher's exact test) revealed increasing significance for the vitrectomy group 1, 3, and 6 months after enrollment ($P = .03$ to .004 and $P = .03$ to .005, respectively).

a minimum of 6 and a maximum of 18 months; grid laser photocoagulation performed at least 4 months earlier; a documented attached posterior hyaloid either with B-scan ultrasound examination or the presence of a preretinal membrane shown with optical coherence tomography (OCT); and no or only mild cataract, less than NO3NC3C3P3 according to the Lens Opacities Classification System III (LOCS III) charts.

Excluded were patients who had had more than three laser treatments in the macula or other pretreatments before enrollment, long-term treatment with diuretics, or HbA_{1c} of more than 8.0.[24,25] Eyes with ischemic maculopathy, proliferative changes with indication for panretinal laser coagulation, optic atrophy or advanced glaucoma, lens opacification more than NO3NC3C3P3 according to the LOCS III charts, patients receiving hemodialysis, and those unable to return to follow-up examinations were not included.

When fulfilling the inclusion criteria, patients were informed about the idea of the study. After consent to participate, an envelope was opened and the eye was randomized either to a vitrectomy group I (Gr I) or to a control group II (GR II). A written informed consent was obtained from all patients. Patients were followed up for 6 months. Evaluations were carried out at baseline and 1, 3, and 6 months after enrollment. Measurements of blood glucose level, blood pressure, and HbA_{1c} were included in the follow-up.

Examinations included biomicroscopy of the anterior and posterior segment, a functional assessment for far and near distances, and an evaluation of morphologic changes using OCT measurements of the retinal thickness and B-scan ultrasound examinations. Fluorescein angiograms (Heidelberg Retina Angiograph, Heidelberg Engineering GmbH, Heidelberg, Germany) were taken at each control. All examinations were done at the same time of day by two independent ophthalmologists uninvolved in the selection and surgery of patients and without knowledge as to which group the patient belonged. The average of the two measurements was taken.

Distance acuity was tested with ETDRS charts under constant illumination density at a distance of 2 m with an addition of 0.75 spherical diopters to the best correction for far distance. The letter score was multiplied with 0.01 for statistical calculation.

The reading ability was examined with Jaeger (Jg) charts at a distance of approximately 25 cm with an addition of four spherical diopters to the best correction for far distance. This test regimen was not changed in the follow-up examinations. On these charts, Jg 1 represents the smallest and Jg 16 the largest type text. No reading acuity was registered as Jg 17.

To avoid temporal variations in macular edema thickness,[26] OCT was always taken in the morning with the Humphrey Optical Coherence Tomograph 2 (Carl Zeiss, Humphrey Systems, Germany) through dilated pupils. The OCT examination consisted of six radial 6-mm-long scans of each eye, centered on the patient's fixation point, at intervals of 30 degrees. Retinal thickness was computed automatically using OCT retinal mapping software. This mapping averaged the six scans to give the central macular thickness in an area 500 μm in diameter, that is, the average of 50 measurements.

Univariate analysis was performed to compare the functional results of both groups for far and near distances (χ-square test and tailed Fisher's exact test) at each time point during follow-up. *P* values of less than .05 were assessed as significant.

Main outcomes were judged as follows:

- Changes of at least 10 letters in visual acuity for far evaluated with ETDRS charts in 2 m representing better (plus 10 or more letters), same, or worse (minus 10 or more letters).
- Changes of more than 2 lines in visual acuity for near using Jg charts representing better (minus 2 or more lines), same, or worse (plus 2 or more lines).

TABLE 2. Results of Reading Visual Acuity in Eyes Following Vitrectomy for Diffuse Diabetic Macular Edema (OP I) Compared with an Unoperated Control Group (CO II)*

Time (mo after enrollment)	Group	Worsened > 2 lines	No Change	Improved > 2 lines	*P* value for chi-Square	Fisher's Exact Test *P* value (2-Tail)
1	OP I	2 (8%)	16 (64%)	7 (28%)	.43365	.46884
	CO II	5 (16.1%)	21 (67.7%)	5 (16.1%)		
3	OP I	2 (8%)	16 (64%)	7 (28%)	.33448	.36998
	CO II	7 (22.6%)	17 (54.8%)	7 (22.6%)		
6	OP I	3 (12%)	12 (48%)	10 (40%)	.01666	.01790
	CO II	10 (32.3%)	18 (58.1%)	3 (9.7%)		

The results are listed in absolute numbers of patients and percentages due to changes of more than 2 lines in both directions or unchanged values. Statistical evaluation (chi-square and Fisher's exact test) revealed significance for the vitrectomy group only 6 months after enrollment ($P = .016$ and .017, respectively).

Multivariate analysis was performed to test the evolution of all three scores (ETDRS, Jg, OCT). For each of the scores, mixed models for the levels (absolute levels) as well as for the differences to baseline were used. Time since the date of operation, a dummy variable for therapy, and the interaction of these two terms were included in each regression. The baseline value, age, and gender were also included as covariates. For the regressions using the differences, the time variable was used as a categorical variable and the least-squares means of the groups were compared. The models in levels included time as a continuous variable, so covariance analysis was performed by comparing slopes and intercepts of the regressions fitted for both groups.

Surgery was performed under general anesthesia by two surgeons (S.B., U.S.). A standard three-port vitrectomy was combined with removal of the posterior hyaloid. The internal limiting membrane (ILM) was stained with 0.1 ml of a 0.125% indocyanine green (ICG) solution for 30 seconds and removed with an end-gripping forceps. In patients who had mild cataract and who were older than 60 years, phacoemulsification of the lens with posterior chamber lens implantation was performed as a combined procedure. Postoperatively, topical antibiotic and anti-inflammatory therapy was administered three times daily over 4 weeks in both groups.

RESULTS

FIFTY-SIX PATIENTS FULFILLED THE STUDY CRITERIA. ALL patients completed the 6-month examination; there were no dropouts during follow-up, and no data were missing for statistical analysis. One patient experienced a stroke after the 3 months control but could perform the final evaluation. In both groups, antihypertensive therapy was not changed and HbA_{1c} was kept under 8.0. The mean age was 61.4 years (range 28 to 74), 30.3% (17 of 56) were male, and 69.7% (39 of 56) were female.

Twenty-five eyes (44.6%) were randomized into Gr I (vitrectomy group) and 31 eyes (55.4%) to Gr II (controls). Both groups were comparable in mean age (62.7 years in Gr I and 63.9 years in Gr II) and gender (two thirds were female, one third was male). Six eyes in each group (21.4%; 12 of 56) were pseudophakic before enrollment.

Surgery was uneventful in all cases. In 32% (8 of 25) of the eyes, vitrectomy was combined with extraction of the mild cataract and posterior chamber lens implantation.

During the early postoperative course, minimal cell flare in the anterior chamber was present in 28% (7 of 25) of the eyes operated on, which was sufficiently treated topically. There was no rise of the intraocular pressure. In two cases, a vitreous hemorrhage developed 5 and 10 days, respectively, after surgery and resolved spontaneously after 4 weeks in both eyes. In the control group (Gr II), B-scan ultrasound revealed no spontaneous separation of the posterior vitreous surface during follow-up examinations. The lens status was determined at each control and did not differ from the baseline examination.

Biomicroscopy showed an absorption of the edema at the final examination in 48% (12 of 25) of the eyes in Gr I compared with 22.7% (7 of 31) of the eyes in Gr II. In one eye of Gr I, a recurrent edema occurred after 3 months, leading to visual deterioration.

Final fluorescein angiograms showed a decreased leakage in the macula in 60% (15 of 25) of the eyes operated on, compared with 26.3% (8 of 31) of the control eyes.

Visual acuity results for far are shown in Table 1 (). At baseline, ETDRS visual acuity ranged between 0.02 and 0.72, with an average of 0.28 in the vitrectomy group and 0.35 in the control group.

One month after surgery, 52% (13 of 25) of Gr I were improved in comparison to 19.4% (6 of 31) of Gr II. Twenty-eight percent (7 of 25), compared with 54.9% (17of 31), were unchanged. Twenty percent (5 of 25) of the eyes in Gr I deteriorated, two of those due to a vitreous hemorrhage. In Gr II, 25.8% (8 of 31) of the eyes were

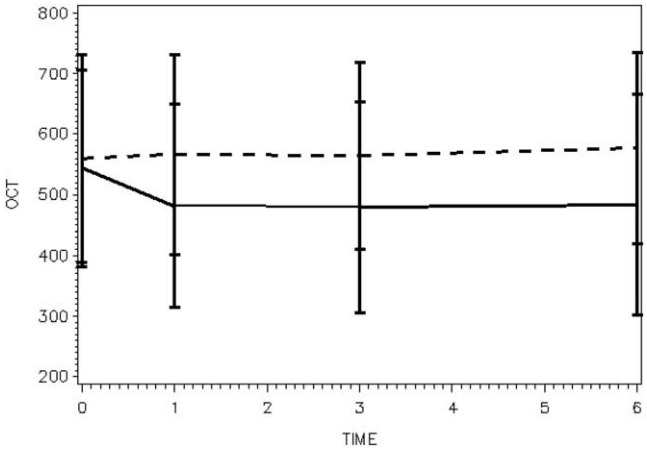

FIGURE. Mean retinal thickness over time in patients following vitrectomy for diffuse diabetic macular edema. There is a significant decrease in the operation group after 1 month (solid line) but no significant change thereafter. In the control group (dotted line), a slight increase was found over time.

worse at this time. The average visual acuity was 0.30 in Gr I (range 0.04 to 0.72) and 0.34 in Gr II (range 0.02 to 0.72).

Three months postoperatively, 40% (10 of 25) of the eyes in Gr I compared with 12.9% (4 of 31) in Gr II were improved, whereas preoperatively, 44% (11 of 25) remained unchanged in Gr I versus 48.4% (15 of 31) in Gr II. Deterioration was found in 16% (4 of 25) in Gr I; one of those showed a marked recurrent edema. In Gr II, 38.7% (12 of 31) were worse. The average visual acuity was 0.31 in the vitrectomy group (range 0.02 to 0.64) and 0.29 in the control group (range 0 to 0.64).

At the 6-month follow-up, 52% (13 of 25) of the eyes in Gr I versus 12.9% (4 of 31) in Gr II showed an increased vision compared with initially. Thirty-two percent (8 of 25) in Gr I compared with 45.2% (14 of 31) in Gr II were stable, and 16% (4 of 25) in Gr I versus 42% (13 of 31) in Gr II deteriorated. The mean visual acuity was 0.32 (range 0.04 to 0.78) in the vitrectomy group and 0.28 (range 0 to 0.84) in the control group.

Statistically significant differences at the 5% level in the distribution of outcomes preferring the vitrectomy group were shown at all time points with P values from .03 to .004 (χ^2 test) and .035 to .005 (Fisher's exact test). The highest significance was achieved for the final results. Multivariate analysis revealed a statistically significant negative change in the average visual acuity over time in the control group compared with baseline values ($P = .03$ for the time*therapy interaction term). There was a significant correlation with age, showing better results for younger patients ($P = .0165$).

Visual acuity results for near are shown in Table 2 (). At baseline, reading vision ranged between Jg 2 and 17 with an average of 12.2 in Gr I and 9.2 in Gr II.

After 1 month, an improvement of 2 or more lines was achieved in 28% (7 of 25) in Gr I compared with 16.1% (5 of 31) in Gr II. Sixty-four percent (16 of 25) in Gr I as opposed to 68.1% (21 of 31) in Gr II remained stable, and 8% (2 of 25) in Gr I compared with 16.1% (5 of 31) in Gr II deteriorated. The mean visual acuity was 11.28 (range 3 to 17) in the vitrectomy group and 8.9 (range 3 to 17) in the control group.

Three months after surgery, seven eyes improved 2 or more lines in both groups (28% in Gr I and 22.6% in Gr II). Sixty-four percent (16 of 25) of the eyes in Gr I and 54.8% (17 of 31) of the eyes in Gr II were unchanged. Eight percent (2 of 25) in Gr I compared with 22.6% (7 of 31) in Gr II worsened. The mean value was 10.88 (range 2 to 17) in the vitrectomy group and 9.16 (range 3 to 17) in the control group.

At 6 months, 40% (10 of 25) in Gr I compared with 9.7% (3 of 31) in Gr II achieved a better reading vision, 48% (12 of 25) in Gr I compared with 58.1% (18 of 31) in Gr II were stable, and 12% (3 of 25) in Gr I compared with 32.3% (10 of 31) in Gr II deteriorated. The mean visual acuity was 11.16 (range 2 to 17) in the vitrectomy group and 10.35 (range 3 to 17) in the control group.

Univariate analysis revealed no statistical significance after 1 and 3 months (P values .33 to .46). At the final examination the vitrectomy group had significantly better results than the control group ($P = .01$). In the multivariate analysis there was no statistically significant change in average for the vitrectomy group. The control group, however, showed a significant increase in the Jg score equivalent to a significant decrease of the reading vision during follow-up ($P = .0136$).

OCT results are shown in the (Figure). At baseline, the mean foveal retinal thickness was 543.9 μm (range 412 to 722) in Gr I and 559.6 μm (range 402 to 710) in Gr II.

One month later, these values decreased significantly to 481.7 μm (range 279 to 712) in Gr I but remained unchanged in Gr II (mean 566.6, range 418 to 722).

At months 3 and 6, there were no more significant changes in both groups ($P = .6$ to .8). Finally, the mean foveal retinal thickness was 483.6 μm (range 268 to 722) in Gr I and 577.3 μm (range 425 to 724) in Gr II.

The mean change of macular thickness in both groups during follow-up was statistically significant. P values were $<.0001$ for months 1, 3, and 6 preferring the vitrectomy group. At all time points, the results in Gr I were significantly better compared with baseline ($P < .0001$), whereas in Gr II there was no significant change to initial values ($P = .4$ to .1).

DISCUSSION

MACULAR EDEMA ASSOCIATED WITH DIABETIC RETINOPAthy is one of the main causes of visual acuity impairment in patients with diabetes. According to a population-based

study, edema within 1 disk diameter of the center of the macula was found in 9% of the diabetic population, approximately 40% of whom had central macular involvement resulting in visual deterioration.[1,7,8]

The pathogenesis of diabetic macular edema is multifactorial, implicating duration of diabetes, insulin dependence, highly glycosylated hemoglobin, proteinuria, hypertension, and panretinal laser photocoagulation.[1,8–10] The mechanism underlying the formation of diabetic edema is still unknown. The important pathology is the loss of pericytes in retinal capillaries leading to an increased permeability.[27] Nasrallah and colleagues[28,29] reported that the vitreous may play an important role in the development of macular edema. Sebag and associates[30,31] demonstrated a high level of enzyme-mediated vitreous collagen cross-linking and nonenzymatic glycation in the human diabetic vitreous, probably affecting the collagen structure and causing destabilization of the gel structure of the vitreous. Such alteration of the vitreous attached to the retina could induce condensation and traction on the macula and contribute to the persistence of edema.[32] Furthermore, various mediators that infiltrate the vitreous as a result of the breakdown of the blood-retinal barrier and induce macular edema remain in close contact to the macula in case of vitreomacular adhesion.[33] Glycemia-related molecular changes may also alter and thicken the posterior vitreous surface, leading to less permeability and a high concentration of chemical mediators.[30,31]

Several retrospective clinical studies showed that vitrectomy and removal of the posterior hyaloid lead to visual improvement of 2 or more lines in 38% to 92% of the eyes.[12–21] These studies include small series with high success rates of 85% to 92%.[12,15,16] In larger series of Tachi and Ogino,[14] Pendergast and associates,[19] LaHeij and colleagues,[21] Yamamoto and associates,[20] and Ndoye Roth and colleagues,[22] a functional benefit after vitrectomy in approximately 50% of the cases was described.

The necessity of ILM peeling is still unclear. Gandorfer and associates[16] achieved the highest success rate (92%) after vitrectomy and ILM peeling, in a small series, whereas Kumagai and colleagues[34] found no difference in the absorption rate of macular edema (more than 90%) or of the functional outcome, in a larger series, after vitrectomy with or without ILM peeling. In our series, ILM peeling was performed in all vitrectomy eyes based on our experience with earlier nonrandomized cases. To minimize potential toxic effects, ICG was diluted with 5% glucose solution, injected in an amount of 0.1 ml, and left for 30 seconds without illumination.

However, Hikichi and associates[23] evaluated the natural course of diabetic macular edema associated with the vitreomacular relationship. They observed a spontaneous resolution of the edema in 55% of the eyes with an vitreomacular separation, in comparison with 25% of the eyes with vitreomacular adhesion. Visual acuity improved in 36%, compared with 15% during an observation time of 6 months, which is comparable to the results in the control group (13% to 19%).

On the basis of these results, we prospectively compared two randomized groups of eyes with diabetic macular edema. The outcome for distance visual acuity turned out to always be significantly better in eyes undergoing operation than in controlled eyes ($P = .03$ to $.004$). The percentage of eyes that improved more than 2 lines was 52% at the final examination, which corresponds well with the results of the aforementioned studies.[14,19,20] Although a significant change could not be found for reading vision within 3 months after enrollment, the eyes operated on have a significantly better reading vision than the eyes of the control group ($P = .01$) at the end point.

The multivariate analysis of ETDRS and Jg values gave us additional information. The average scores showed a trend in favor of Gr I but did not change significantly over time compared with the baseline scores in both groups. The control group, however, showed a significant decrease in reading vision during follow-up. The interaction therapy*time was significant and negative for ETDRS vision, confirming a decrease with time for the control group. Larger case series and longer observation time might become helpful to explore these results further. As expected, the coefficient for age was also significant and negative, implying a decreased score for older patients, which means a better prognosis for younger patients.

The multivariate analysis of the OCT measurements showed a markedly different behavior between both groups. Whereas the control group achieved on-average stable values, there was a sharp decrease in the vitrectomy group (significance $P < .0001$) after 1 month, which then stabilized ($P = .6$ to $.8$). The differences between both groups were highly significant at any time ($P < .0001$).

A previous study by Yamamoto and associates[20] also demonstrated a marked reduction of retinal thickness 7 days after vitrectomy, which then remained unchanged for approximately 1 month. This effect could be observed until 4 months postoperatively. They suggested that an improved oxygen concentration caused retinal vasoconstriction with subsequent decrease of leakage, as also postulated by Stefansson and colleagues.[35,36]

The evaluation in the present randomized study showed a more distinct morphologic effect of the surgery on the macular thickness than a functional effect, which was higher in ETDRS vision than in reading vision. There was a significant correlation to age, probably expecting better results when vitrectomy is performed earlier. In addition, these results might become better if no grid laser treatment has been performed before surgery, which was already stated by LaHeij and associates.[21]

The role of development of postoperative cataract is always difficult to assess in vitrectomy studies in an elderly population. The LOCS III system was used, therefore, to ensure that only patients with very mild cataract were included and to grade potential changes. Because of the

more rapid development of nuclear sclerosis after vitrectomy in elderly patients,[37] a combined surgery was performed in our study in patients older than 60 years. We strongly believe that the pros and cons compensate, because in two thirds of the patients only vitrectomy was performed, and in one third a combined surgery was performed. However, we cannot completely exclude that cataract surgery might have an impact on the functional results.

To our current knowledge, this is the first prospective randomized trial on vitrectomy for diffuse diabetic macular edema. Its weakness is the rather small number of cases and potentially too short follow-up. Larger numbers and longer observation time might provide us with additional information about the value of vitreous surgery in the treatment of diffuse diabetic macular edema, which is a disease of multifactorial origin. However, in eyes with an adherence of the vitreous, the mechanical removal of the vitreous and the release of adherent membranes in the foveal area seem to be one of the main influencing factors.

In conclusion, we provide evidence that vitrectomy with ILM peeling is superior to observation in eyes with persistent diffuse diabetic macular edema for at least 6 months and positively influences distance and reading visual acuity as well as the morphology of the edema. However, to exclude temporary improvements,[38] longer follow-up and larger series will be needed to confirm these data.

REFERENCES

1. Klein R, Klein BE, Moss SE, Davis MD, DeMets DL. The Wisconsin Epidemiologic Study of Diabetic Retinopathy, IV: diabetic macular edema. Ophthalmology 1984;91: 1464–1474.
2. Early Treatment of Diabetic Retinopathy Study Research Group. Photocoagulation for diabetic macular edema. Early Treatment Diabetic Retinopathy Study report number 1. Arch Opthalmol 1985;103:1796–1806.
3. Bresnick GH. Diabetic maculopathy. A critical review highlighting diffuse macular edema. Ophthalmology 1983;90: 1301–1317.
4. Olk RJ. Modified grid blue-green laser photocoagulation for diffuse diabetic macular edema. Ophthalmology 1986;93: 938–950.
5. Lee CM, Olk RJ. Modified grid laser photocoagulation for diffuse diabetic macular edema: long-term visual results. Ophthalmology 1991;98:1594–1602.
6. Ulbig MW, McHugh JDA, Hamilton AMP. Focal diode laser treatment for diabetic macular edema. Br J Ophthalmol 1995;79:318–321.
7. Ferris FL, Patz A. Macular edema: a complication of diabetic retinopathy. Surv Ophthalmol 1984;28(Suppl): 452–461.
8. Klein R, Moss SE, Klein BEK, et al. The Wisconsin Epidemiologic Study of Diabetic Retinopathy, XI. The incidence of macular edema. Ophthalmology 1989;96:1501–1510.
9. Perkovich BT, Meyers SM. Systemic factors affecting diabetic macular edema. Am J Ophthalmol 1988;105:211–212.
10. McDonald HR, Schatz H. Macular edema following panretinal photocoagulation. Retina 1985;5:5–10.
11. Nasrallah FP, Jalkh AE, VanCoppenrolle F, et al. The role of the vitreous in diabetic macular edema. Ophthalmology 1988;95:1335–1339.
12. Lewis H, Abrams GW, Blumenkranz MS, Campo RV. Vitrectomy for diabetic macular traction and edema associated with posterior hyaloid traction. Ophthalmology 1992; 99:753–759.
13. Harbour JW, Smiddy WE, Flynn HW, Rubsamen PE. Vitrectomy for diabetic macular edema associated with a thickened and taut posterior hyloid membrane. Am J Ophthalmol 1996;121:405–413.
14. Tachi N, Ogino N. Vitrectomy for diffuse macular edema in cases of diabetic retinopathy. Am J Ophthalmol 1996;122: 258–260.
15. Yang CM. Surgical treatment for severe diabetic macular edema with massive hard exudates. Retina 2000;20:121–125.
16. Gandorfer A, Messmer EM, Ulbig MW, Kampik A. Resolution of diabetic macular edema after surgical removal of the posterior hyloid and the inner limiting membrane. Retina 2000;20:126–133.
17. Otani T, Kishi S. Tomographic assessment of vitreous surgery for diabetic macular edema. Am J Ophthalmol 2000;129: 487–494.
18. Otani T, Kishi S. A controlled study of vitrectomy for diabetic macular edema. Am J Ophthalmol 2002;134:214–219.
19. Pendergast SD, Hassan TS, Williams GA, et al. Vitrectomy for diffuse diabetic macular edema associated with a taut premacular posterior hyloid. Am J Ophthalmol 2000;130: 178–186.
20. Yamamoto T, Hitani K, Tsukahara I, et al. Early postoperative retinal thickness changes and complications after vitrectomy for diabetic macular edema. Am J Ophthalmol 2003;135:14–19.
21. LaHeij EC, Hendrikse F, Kessels AGH, Derhaag P. Vitrectomy results in diabetic macular oedema without evident vitreomacular traction. Graefes Arch Clin Exp Ophthalmol 2001;239:264–270.
22. Ndoye Roth PA, Grange JD, Hajji Z. Diabetic cystoid macular edema and vitrectomy. Preliminary results: about 19 cases. J Fr Ophtalmol 2003;26:38–46.
23. Hikichi T, Fujio N, Akiba Y, Takahashi M, Yoshida A. Association between the short-term natural history of diabetic macular edema and the vitreomacular relationship in type II diabetes mellitus. Ophthalmology 1997;104:473–478.
24. Aroca PR, Salvat M, Fernandez J, Mendez I. Risk factors for diffuse and focal macular edema. J Diabetes Complications 2004;18:211–215.
25. Ciardella AP. Partial resolution of diabetic macular edema after systemic treatment with furosemide. Br J Ophthalmol 2004;88:1224–1225.
26. Frank RN, Schulz L, Abe K, Iezzi R. Temporal variation in diabetic macular edema measured by optical coherence tomography. Ophthalmology 2004;111:211–217.

27. Frank RN. Etiologic mechanisms in diabetic retinopathy. In: Ryan SJ, editor. Retina, 2nd ed. Volume 2. St Louis: CV Mosby, 1994;1243–1276.
28. Nasrallah FP, Jalkh AE, Van Coppenolle F, et al. The role of the vitreous in diabetic macular edema. Ophthalmology 1988;95:1335–1339.
29. Nasrallah FP, Van de Velde F, Jalkh AE, et al. Importance of the vitreous in young diabetics with macular edema. Ophthalmology 1989;96:1511–1517.
30. Sebag J, Buckingham B, Charles MA, Reiser K. Biochemical abnormalities of vitreous in humans with proliferative diabetic retinopathy. Arch Ophthalmol 1992;110:1472–1476.
31. Sebag J, Nie S, Reiser K, et al. Raman spectroscopy of human vitreous in proliferative diabetic retinopathy. Invest Ophthalmol Vis Sci 1994;35:2976–2980.
32. Sebag J, Balazs EA. Pathogenesis of CME: anatomic consideration of vitreoretinal adhesions. Surv Ophthalmol 1984; 29(suppl):493–498.
33. Cunha-Vas J, De Abreu JRF, Campos AJ, Figo GM. Early breakdown of the blood-retinal barrier in diabetes. Br J Ophthalomol 1975;59:649–656.
34. Kumagai K, Ogino N, Furukawa M, et al. Internal limiting membrane peeling in vitreous surgery for diabetic macular edema. Nippon Ganka Gakkai Zasshi 2002;106: 590–594.
35. Stefansson E, Landers MB, Wolbarsht ML. Increased retinal oxygen supply following panretinal photocoagulation and vitrectomy and lensectomy. Trans Am Ophthalmol Soc 1981;79:307–334.
36. Stefansson E, Novack RL, Hatchell DL. Vitrectomy prevents retinal hypoxia in branch retinal vein occlusion. Invest Ophthalmol Vis Sci 1990;284–289.
37. Smiddy WE, Feuer W. Incidence of cataract extraction after diabetic vitrectomy. Retina 2004;24:574–581.
38. Micelli Ferrari T, Cardascia N, Durante G, Vetrugno M, Cardia L. Pars plana vitrectomy in diabetic macular edema. Doc Ophthalmol 1999;97:471–474.

Biosketch

Ulrike Stolba, MD, has worked at the Department of Ophthalmology, Rudolf Foundation Hospital Vienna, Austria; Department of Ophthalmology, University Eye Clinic, Vienna, Austria; Department of Ophthalmology, University Eye Clinic, Vienna, Austria. From 1986 to 1995, she studied at the Department for Vitreoretinal Diseases at the Department of Ophthalmology, University Eye Clinic, Vienna, Austria and at the Department of Ophthalmology, University of Vienna, Austria. Dr. Stolba has published 54 articles in English, German and French, and has contributed 10 book chapters. Her main interests are microsurgery, especially vitreoretinal surgery, diagnosis and treatment of AMD and diabetic complications, research in vitreous substitutes, AMD, and diabetes.

Biosketch

Susanne Binder, MD, has been the chairman of the Department of Ophthalmology, Rudolf Foundation Clinic, since 1995, and has also been chairman of the Ludwig Boltzmann Institute of Retinology and Biomicroscopic Laser Surgery since 1997, both in Vienna, Austria. In addition, Dr. Binder has worked at the University Eye Clinic B, Vienna General Hospital, University of Vienna Medical School, Vienna, Austria; Professor of Ophthalmology, University Eye Clinic, Vienna, Austria; Vitreoretinal Diseases, First University Eye Clinic, Vienna, Austria. She has published 142 articles in English and German, edited two books, published 30 surveys and book chapters, in addition to 24 miscellaneous articles. As an editor, Dr. Binder has served on the editorial board of Graefe's Arch Clin Exp Ophthalmol;Ophthamologica; the editor-in-chief of Spektrum der Augenheilkunde, The Journal of the Austrian Ophthalmological Society. Primary interests include microsurgery, vitreoretinal surgery and -diseases, research in AMD, especially retinal transplantation, retinal vascular diseases. She is a member of AAO, ARVO, Retina Society, Association of Retinal Specialists, Club Jules Gonin, and other national and international societies.