



Accuracy of endoscopic ultrasonography in diagnosing ascites and predicting peritoneal metastases in gastric cancer patients

Y T Lee, E K W Ng, L C T Hung, S C S Chung, J Y L Ching, W Y Chan, W C Chu and J J Sung

Gut 2005;54;1541-1545; originally published online 13 Jun 2005;
doi:10.1136/gut.2004.055772

Updated information and services can be found at:
<http://gut.bmjournals.com/cgi/content/full/54/11/1541>

These include:

References

This article cites 30 articles, 4 of which can be accessed free at:
<http://gut.bmjournals.com/cgi/content/full/54/11/1541#BIBL>

Email alerting service

Receive free email alerts when new articles cite this article - sign up in the box at the top right corner of the article

Topic collections

Articles on similar topics can be found in the following collections

[Stomach and duodenum](#) (565 articles)
[Other imaging techniques](#) (1466 articles)
[Cancer: gastroenterological](#) (1187 articles)

Notes

To order reprints of this article go to:
<http://www.bmjournals.com/cgi/reprintform>

To subscribe to *Gut* go to:
<http://www.bmjournals.com/subscriptions/>

GASTRIC CANCER

Accuracy of endoscopic ultrasonography in diagnosing ascites and predicting peritoneal metastases in gastric cancer patients

Y T Lee, E K W Ng, L C T Hung, S C S Chung, J Y L Ching, W Y Chan, W C Chu, J J Sung



Gut 2005;54:1541-1545. doi: 10.1136/gut.2004.055772

See end of article for authors' affiliations

Correspondence to:
Dr Y T Lee, Department of
Medicine and
Therapeutics, The Chinese
University of Hong Kong,
Prince of Wales Hospital,
Shatin NT, Hong Kong,
China; leeytong@
cuhk.edu.hk

Revised version received
15 March 2005
Accepted for publication
10 May 2005
Published online first
13 June 2005

Background: Preoperative diagnosis of peritoneal metastases (PM) is difficult in patients with gastric cancer (GC).

Aims: To assess the accuracy of endoscopic ultrasonography (EUS) in diagnosing ascites and its predictability for the presence of PM in GC patients.

Subjects: Consecutive patients with newly diagnosed GC from 1998 to 2004 were studied.

Methods: All patients underwent EUS, ultrasound (US), and computed tomography (CT) scan for preoperative staging and the presence of ascites. The results were compared with operative findings. The diagnosis of PM was confirmed by histopathology or peritoneal fluid cytology.

Results: A total of 301 patients were recruited and in 250 patients the presence of ascites (n = 93) and PM (n = 71) were confirmed. EUS was more sensitive (87.1%) than combined US and CT scan examinations (16.1%) and operative findings (laparoscopy or laparotomy) (40.9%) in diagnosing ascites. Sensitivity, specificity, positive and negative predictive values, and accuracy for predicting the presence of PM were 73%, 84%, 64%, 89%, and 81% by EUS; 18%, 99%, 87%, 75%, and 76% by combining US and CT scan; and 77%, 94%, 83%, 91%, and 89% by operative findings, respectively. In multivariate logistic regression analysis, EUS detected ascites was the only significant independent predictor for the presence of PM (p < 0.001; odds ratio 4.7 (95% confidence interval 2.0-11.2)).

Conclusion: EUS is a sensitive method for diagnosing ascites which is an important predictive factor for the presence of PM in GC patients.

Gastric cancer (GC) is a common malignancy which carries a high mortality rate. The long term prognosis is closely related to tumour stage at the time of presentation. Patients with tumour invading to the serosa have a much worse outcome.¹ Curative surgery is considered impossible if there are distant or peritoneal metastases (PM), which are found in 25-50% of patients with GC at presentation.² Computed tomography (CT) scan has limited resolution in defining different layers of the gastric wall and therefore was shown to be less accurate in the local staging of GC.³⁻⁵ In a study by Adachi *et al*, CT scan failed to detect 27% of PM and 45% of stage IV disease.⁵ Ultrasound (US) and CT scan were also shown to be poor in detecting PM.^{4, 6} The role of positron emission tomography (PET) in the diagnosis of PM is not well defined. In one study it missed all four cases of PM⁷ and in another PET increased the detection rate of PM.⁸ Also, the examination is not widely available and is expensive. Radiologically it is difficult to identify peritoneal deposits but the presence of ascites would suggest such a diagnosis.⁹ However, in patients with GC, the best method for diagnosing ascites has yet to be determined and the predictive value of ascites for the presence of PM is unknown.

Endoscopic ultrasonography (EUS) offers the best preoperative local GC staging, with accuracies in T and N staging of approximately 78% and 70%, respectively.¹⁰ Although EUS is not suitable for diagnosing distant metastases, it may be more useful in detecting ascites due to the close proximity of the echoendoscope to the peritoneum.

The aims of the study were to assess the accuracy of EUS in diagnosing ascites and its predictability for the presence of PM during preoperative GC staging.

PATIENTS AND METHODS

Consecutive patients with adenocarcinoma of the stomach diagnosed in the Prince of Wales Hospital were prospectively recruited into the study from January 1998. All patients were studied preoperatively by EUS to determine local tumour extent (T stage) and lymph node metastases (N stage). The staging classification was based on the 5th UICC TNM classification system published in 1997.¹¹ We used previously reported EUS criteria, namely sharply demarcated margin, round shape, homogeneous hypoechoic pattern, and size greater than 1 cm to diagnose metastatic lymph node.¹² The EUS examination was performed under conscious sedation with the patient lying in the left lateral position. All procedures were performed or supervised by a single endosonographer (YTL). The EUS study was performed with either a GF-UM20 or a GF-UM240 echoendoscope (Olympus, Tokyo, Japan), both equipped with dual scanning frequencies of 7.5 and 12 MHz. Ascites was diagnosed by anechoic space outside the gastrointestinal tract under EUS scanning. A small amount of ascites is usually triangular in shape and the shape will change depending on the peristalsis of the bowel, and the position and breathing of the patient (fig 1).

Abdominal US examination of the upper abdomen and pelvis was performed to look for lymph nodes and liver metastases. Helical CT scan examination of the upper abdomen and pelvis was performed with intravenous and

Abbreviations: EUS, endoscopic ultrasonography; CT, computed tomography; US, ultrasound; GC, gastric cancer; PM, peritoneal metastases; PET, positron emission tomography; PPV, positive predictive value; NPV, negative predictive value; OR, odds ratio

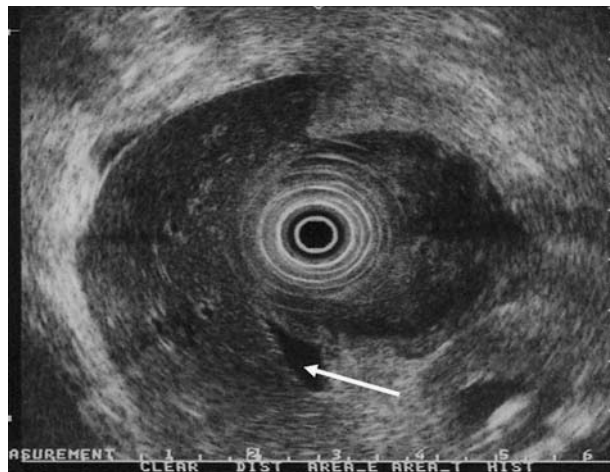


Figure 1 Small amount of ascites (arrow) detected under the right lobe of the liver in a patient with circumferential tumour in the gastric body.

oral contrast enhancement if locally advanced disease or distant metastases were suspected. Ascites and PM were specifically looked for during US and CT scan examinations. All radiological investigations were performed by experienced radiologists. All radiological and EUS investigations were interpreted by independent examiners who were blinded to the results of the other imaging studies.

Surgery was offered to patients who had no distant metastases and were medically fit. Except for radiological T1 cancer, laparoscopy was first performed to look for any ascites and PM. Biopsy was taken for frozen section if peritoneal deposits were suspected (fig 2). When ascites was detected during operation, a sample of ascitic fluid was sent for cytological examination. If no gross metastasis or ascites was found, peritoneal washing with 200 ml warm saline was performed and the washing was sent for cytological examination. In suitable patients, surgery proceeded with the aim of curative resection or a palliative procedure.

As CT scan and US may not be as sensitive as EUS in the diagnosis of ascites, they could not be used as the gold standard for the diagnosis of ascites.^{13 14} Also, tiny amounts (as few as several millilitres) of ascites might not be detected during surgery; a negative operative finding could not exclude the presence of ascites. The diagnosis of ascites was

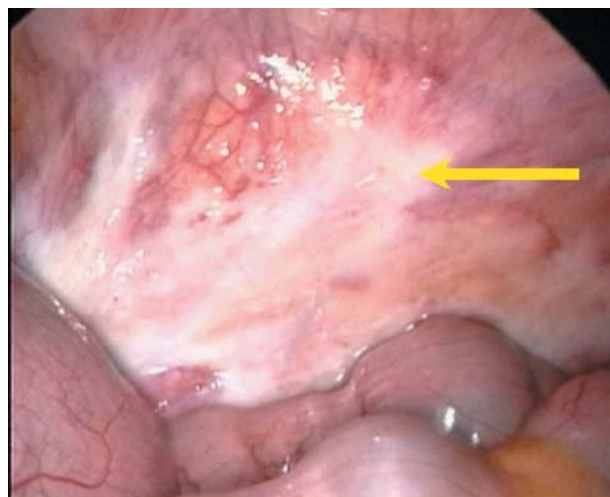


Figure 2 Peritoneal metastases (arrow) were detected by laparoscopy.

based on a combination of laparoscopic findings and characteristic US, CT scan, and EUS images, as described above. Thus if a patient had ascites detected by either laparoscopy, US, CT scan, or EUS, it was considered positive. The presence of PM was verified by histopathology or fluid cytology.

The study protocol was approved by the heads of all of the departments concerned. Written informed consent for endoscopic examination and surgery were obtained from the patients.

Statistics

Sensitivity, specificity, positive predictive value (PPV), negative predictive value (NPV), and accuracy were calculated for EUS alone, US combined with CT scan, and operative (laparoscopy or laparotomy) findings for diagnosing ascites and PM. The χ^2 test was used to calculate the association between EUS diagnosed ascites and T and N stages, tumour subtypes, and differentiation. Factors that might predict the presence of PM were identified by univariate analysis. These variables were then entered into a stepwise multiple logistic regression analysis. Kaplan-Meier life table analysis was used to estimate survival curves and differences were compared by the log rank test. Prognostic factors with statistical significance by univariate analysis were evaluated for prognostic usefulness by multivariate analysis using Cox's proportional hazards model. All tests of significance were two tailed with a p value less than 0.05 taken as statistically significant.

RESULTS

From January 1998 to January 2004, 301 consecutive GC patients were examined by EUS. In 60 patients, operations were not done due to advanced diseases (n=30), which included eight patients with gross peritoneal deposits, as demonstrated by EUS, and 13 with liver metastases and bony metastases, as demonstrated by CT scan, poor pre-morbid state (n=7), refusal of surgery (n=14), and presence of malignant cell in ascitic fluid obtained by paracentesis (n=9). A total of 241 patients underwent laparoscopy or laparotomy in which T stages were determined. Forty nine patients had pT1, 41 had pT2, 111 had pT3, and 40 had pT4 cancer. Accuracy rates of EUS staging for pT1, pT2, pT3, and pT4 cancers were 88%, 80%, 80%, and 94%, respectively. In 32 patients, radical lymph node resections were not done due to the presence of advanced diseases. In another 31 patients, they were recruited into a neoadjuvant chemotherapy programme after laparoscopy, and gastrectomy was performed after completion of the cytotoxic treatment. Reliable

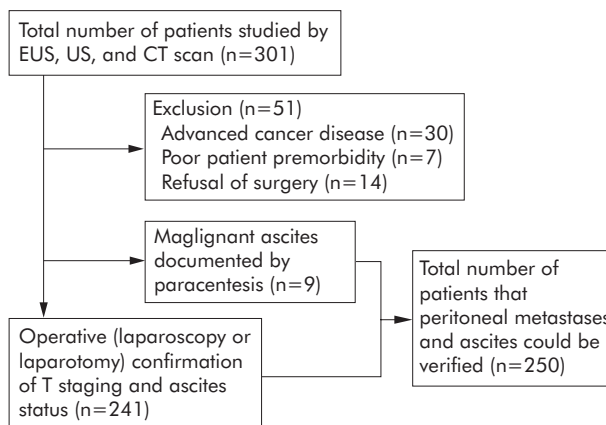


Figure 3 Study profile. EUS, endoscopic ultrasonography; CT, computed tomography; US, ultrasound.

Table 1 Correlation of the detection of ascites by endoscopic ultrasonography (EUS), ultrasound (US) and computed tomography (CT) scan, and laparoscopy and laparotomy in gastric cancer patients with or without peritoneal metastases (PM)

	EUS (n = 250)		US/CT (n = 250)		Laparoscopy/laparotomy (n = 250)*	
	Ascites (+)	Ascites (-)	Ascites (+)	Ascites (-)	Ascites (+)	Ascites (-)
PM+ve	52	19	13	58	27*	44
PM-ve	29	150	2	177	11	168

*Best case scenario—see text.

N stages that could be used to compare with EUS findings were available in 178 patients only. Seventy four patients had pN0, 35 had pN1, 41 had pN2, and 28 had pN3 disease. Accuracy rates of EUS staging for pN0, pN1, pN2, and pN3 diseases were 68%, 72%, 78%, and 86%, respectively. The study profile is summarised in fig 3.

For studying the detection rate of ascites by US, CT, EUS, and operative methods, and its relationship with PM, a subgroup of 250 patients were used (241 patients had undergone operations and nine patients had preoperative paracentesis showing positive malignant cells). There were 160 males and 90 females with a mean age of 60.3 (13.2) years (range 32–88). Of these, 99 patients had CT scans and 231 patients had undergone US. A total of 93 patients (37.2%) had ascites documented by either US, CT scan, EUS, or laparoscopic examination. EUS failed to diagnose ascites in two cases that were seen by US and CT scan. Laparoscopy or laparotomy diagnosed 10 patients with ascites that were missed by EUS, US, and CT scan. Sensitivity values in diagnosing ascites in this subgroup of GC patients were 87.1% (81/93) for EUS, 16.1% (15/93) for combined US (n = 83) and CT scan (n = 47), and 40.9% (38/93) for operative findings in best case scenario, respectively (assuming the nine patients with positive malignant cells detected by paracentesis also underwent operation) (table 1).

Among the 241 patients who underwent surgery, after completion of the radiological and EUS examinations, 202 (84%) patients underwent operation in less than 21 days (median 11 days). In 39 patients the operations were delayed for more than three weeks (22–52 days; median 28.5 days) for various reasons, including optimisation of medical conditions, patient's indecision for surgery, and the SARS outbreak. In 10 patients that had ascites detected during surgery but not by EUS, CT, or US, the delay in operation was 1–14 days (median 9.5 days).

Seventy one (28.4%) patients were diagnosed as having PM, 44 patients by peritoneal biopsy and 27 patients by peritoneal fluid cytology. Correlation of the finding of ascites with the presence of PM is summarised in table 1. Sensitivity, specificity, PPV, NPV, and accuracy in predicting the presence of PM by diagnosing ascites were 73%, 84%, 64%, 89%, and

Table 2 Correlation of peritoneal metastases (PM) detected during operation (n = 241) with the presence of ascites

	PM detected in the operative group (n = 62)	
	Gross PM	Only positive fluid cytology
Ascites+ve	16	2
Ascites-ve	28	16

Table 3 Operative findings and relationship with peritoneal metastases (PM)

	Laparoscopy/laparotomy (n = 250)*	
	Gross PM or ascites	No PM or ascites
PM+ve	55*	16
PM-ve	11	168

*Best case scenario—see text.

81% for EUS and 18%, 99%, 87%, 75%, and 76% for combined US and CT scan examinations. In the 241 patients who underwent laparoscopy or laparotomy, the diagnosis of ascites and its relationship with PM is summarised in tables 1–3.

Therefore, during laparoscopy or laparotomy, sensitivity, specificity, PPV, NPV, and accuracy in predicting the presence of PM by either biopsy of suspicious lesion or detecting ascites were 77%, 94%, 83%, 91%, and 89%, respectively, in the best case scenario (table 3). There was no statistically significant difference between EUS and operative findings in sensitivity (p = 0.46), NPV (p = 0.6), or accuracy (p = 0.06) in predicting the presence of PM although surgery had significantly better specificity (p < 0.001) and PPV (p < 0.001).

In univariate analysis, advanced age, male sex, diffuse type and poorly differentiated adenocarcinoma, advanced T and N stages, and ascites diagnosed by EUS were associated with the presence of PM. In multivariate logistic regression analyses, only ascites diagnosed by EUS was independently associated with PM in preoperative staging (p < 0.001; odds ratio (OR) 4.7 (95% confidence interval (CI) 2.0–11.2)).

When EUS diagnosed ascites in patients with GC, it was associated with advanced T stages (p < 0.001, OR 14.6 (95% CI 5.1–41.8)) and the presence of lymph node metastases (p < 0.001; OR 24.4 (95% CI 5.7–104.9)) (table 4).

Also, EUS was associated with diffuse-type GC compared with intestinal-type or mixed-type (p = 0.003), and poorly differentiated GC compared with well and moderately differentiated GC (p = 0.004) (table 5).

In Kaplan-Meier life table analysis, survival rate was poorer in patient with diffuse-type poorly differentiated GC (all p < 0.05), advanced T and N stage, and the presence of PM (all p < 0.001). In multivariate analysis using Cox's hazard proportional model, advanced T and N stages and the presence of PM (all p < 0.001) were significant prognostic predictors (all p < 0.001).

DISCUSSION

The presence of PM in patients with GC precludes curative surgical treatment, and hence early diagnosis will spare patients from unnecessary laparotomy. In the past, pre-operative diagnosis of PM was difficult and in most cases was inferred by the finding of ascites on US or CT.⁹ While the

Table 4 Relationship between tumour T and N stages and the presence of ascites, as detected by endoscopic ultrasonography (EUS)

	T stage (n = 241)		N stage (n = 178)	
	Early (T1-2)	Advanced (T3-4)	N0	Any N
EUS ascites+	4	68	2	42
EUS ascites-	78	91	72	62

Table 5 Relationship between tumour cell type and differentiation and the presence of ascites, as detected by endoscopic ultrasonography (EUS)

	Diffuse	Intestinal	Mixed	Well	Mod	Poor
EUS ascites+	48	28	5	0	21	60
EUS ascites-	62	95	12	15	58	96

n = 250.

presence of ascites in a patient with GC may serve as an important marker to predict the presence of PM, the best method of detecting small volume ascites has yet to be defined.¹⁵⁻¹⁶ Although abdominal US can detect as little as 10 ml of intra-abdominal fluid,¹⁷ it usually requires the accumulation of several hundred millilitres of fluid before ascites can be detected.¹⁵ On the other hand, CT scan may have the advantage for the diagnosis of ascites located in the central abdomen, and transvaginal US in detecting fluid in the Douglas' pouch.¹⁸

Recently, EUS has been introduced as a sensitive imaging modality for ascites associated with gastrointestinal malignancies. From previous studies it has been shown that EUS is superior to CT scan in detecting ascites.¹³⁻¹⁴ Canto and Gislason studied 163 patients who underwent EUS examinations for various malignancies: ascites was detected in 13.5% of patients. Among 15 GC patients, 40% had ascites detected. CT missed 68% of all cases of ascites in that series.¹³ Nguyen and Chang found that ascites was present in 15% of 518 patients who underwent EUS examinations for various indications. Only 17% of patients with ascites were detected by CT scan.¹⁴ Chen *et al* retrospectively analysed the staging results of 57 GC patients and found that both the sensitivity and specificity for EUS in detecting ascites were 100%.¹⁹ In the current study, 37.2% of a subgroup of 250 GC patients had ascites detected. EUS was significantly more sensitive than US, CT scan, laparoscopy, or laparotomy in the detection of ascites, which in the majority of cases manifested as a trace amount of fluid outside the gastrointestinal tract. In another study on a large cohort of GC patient by Chu *et al*, however, relatively less patients were found to have sonographic evidence of ascites (9%); sensitivity was also low (60.7%). This may have been due to the use of a miniprobe for examination which had a lower penetration depth. Therefore, a small amount of ascites outside a large tumour might not be visualised.²⁰

In the current study, we confirmed our early report that the detection of ascites by EUS in patients with GC was significantly associated with PM.²¹ This finding is supported by other studies.¹³⁻²⁰ Chen *et al* however showed no association between ascites, as diagnosed by EUS, and the presence of PM.¹⁹ This may have been due to the retrospective nature of the study in which small amounts of ascites could be missed if not carefully sought. Also, peritoneal lavage was not performed during operation which again lowered the yield for PM detection. In the current study, gross PM were

seen in 44 patients during laparoscopy, and in 18 patients the diagnosis was made by peritoneal fluid cytology. Although we did not perform additional peritoneal lavage in patients with ascites detected during operation, which might have further increased the yield in 11 patients (table 1), it would not have significantly affected the results of EUS in diagnosing PM even if all of the patients were found to have PM (the accuracy for EUS decreased from 81% to 79% and for surgery increased from 89% to 94%). The presence of a positive peritoneal cytology is associated with a poor long term prognosis.²²⁻²⁴ By performing detailed search of the upper gastrointestinal tract during EUS examination and peritoneal lavage during operation, we confirmed that EUS, as a non-operative staging technique, was comparable with operative staging techniques in predicting the presence of PM.

The debate as to whether this small amount of intra-abdominal fluid is physiological or an early sign of PM which could only be detected by EUS has yet to be resolved.¹⁴ The normal peritoneal cavity contains a small amount of serous fluid (less than 100 ml) for lubrication.¹⁶ However, it is uncommon to detect this small amount of fluid during daily EUS examination, except in patients with underlying cardiac, renal, or liver diseases. Although 70 (28%) patients in our study group were suffering from coexisting cardiac, renal, or liver diseases when they underwent the EUS examination, only 14 patients were found to have ascites: six were true positive and eight were false positive for PM. If we excluded these 14 patients, sensitivity, specificity, PPV, NPV, and accuracy for EUS in predicting PM are 71%, 88%, 69%, 89%, and 83% compared with 73%, 84%, 64%, 89%, and 81% when all patients are included. The difference is small. From a clinical point of view, we could not determine with certainty whether the tumour or the comorbidities caused the ascites. Therefore, to avoid selection bias, we did not exclude these patients. However, when ascites is detected in these patients, the result should be interpreted with care. In a retrospective analysis of 571 patients undergoing EUS for various indications, Nguyen and Chang found ascites in 85 patients, and only 22% had ascites progressed to clinically detectable levels during follow up.¹⁴ In the study of Canto and Gislason, the presence of ascites during the staging investigation for various malignancies was found to be an independent predictor of PM.¹³ The development of ascites in patients with intra-abdominal cancer is due to a peritoneal inflammatory response as a reaction to the transclomic metastasis.

In our study, among the 71 patients who were confirmed to have PM, only 16 (22.5%) were not associated with ascites. Therefore, the presence of ascites in a patient with GC should alert the clinician to the possibility of underlying PM.

While EUS guided fine needle aspiration of the ascites is feasible,¹⁴ it was not routinely done as most of the ascites was next to the tumour and passing a needle through the tumour may give rise to a false positive result and increase the chance of peritoneal seeding; only when the fluid is away from the tumour site would we perform EUS-fine needle aspiration to sample the fluid. When there is a large amount of ascites present, we would perform percutaneous paracentesis before operation.

The management of GC depends on correct staging. In patients with advanced disease or peritoneal seeding, neoadjuvant therapy or intraperitoneal chemotherapy may be deemed necessary for selected patients.²⁵⁻²⁶ Routine use of laparoscopic examination before laparotomy to exclude intra-abdominal metastases was also proposed which, however, may increase the workload and strain of scarce resources.²⁷ From the current and previous studies, EUS is accurate for local T and N staging,^{3-10,28} has significant prognostic value, and is as sensitive and accurate as laparoscopic examination in predicting the presence of PM. Although a positive EUS finding of ascites (PPV 64% for PM) could not exclude the patient from receiving potentially curative surgery, we propose the use of EUS to triage patients who are not found to have distant metastases. In patients with ascites diagnosed by EUS, laparoscopy plus laparoscopic lavage should be performed prior to laparotomy²⁹; for those without ascites detected by EUS (NPV 89% for PM), the surgeon could directly proceed to laparotomy and gastric resection.

Despite the superiority of EUS in assessing local staging, detecting ascites, and predicting the presence of PM, EUS may not replace US and CT scan in preoperative GC staging as EUS is not sensitive enough in diagnosing liver and distant metastases.³⁰ Also, EUS could only detect ascites located in the upper abdomen. Fluid in the lower abdomen and Douglas' pouch may be missed. Addition of a transvaginal or transrectal US examination to EUS may be a more effective way of detecting the presence of ascites.¹⁸ Finally, in the presence of obstructing tumour, the sensitivity of EUS may be affected.

In summary, EUS is a highly sensitive method in detecting ascites, even if only in trace amounts. In GC patients, detection of ascites by EUS is predictive for the presence of PM, which implies guarded long term prognosis.

Authors' affiliations

Y T Lee, L C T Hung, J Y L Ching, J J Y Sung, Department of Medicine and Therapeutics, Prince of Wales Hospital, Hong Kong, China

E K W Ng, S C S Chung, Department of Surgery, Prince of Wales Hospital, Hong Kong, China

W Y Chan, Department of Anatomical and Cellular Pathology, Prince of Wales Hospital, Hong Kong, China

W C W Chu, Department of Diagnostic Radiology and Organ Imaging, Prince of Wales Hospital, Hong Kong, China

Conflict of interest: None declared.

Preliminary results of this paper were presented at the 12th International Symposium on Endoscopic Ultrasonography, 11-13 February 2000, Monte-Carlo, Monaco and the abstract was published in *Endoscopy* 2000;**32**:A23, and at Digestive Disease Week, 20-23 May 2001, Atlanta and the abstract was published in *Gastrointest Endosc* 2001;**53**:AB161.

REFERENCES

- Hayes N, Ng EK, Raimes SA, *et al*. Total gastrectomy with extended lymphadenectomy for "curable" stomach cancer: experience in a non-Japanese Asian center. *J Am Coll Surg* 1999;**188**:27-32.
- Lundh G, Burn JI, Kalig G, *et al*. A co-operative international study of gastric cancer. *Ann R Coll Surg Engl* 1974;**54**:219-28.
- Ziegler K, Sanft C, Zimmer T, *et al*. Comparison of computed tomography, endosonography, and intraoperative assessment in TN staging of gastric carcinoma. *Gut* 1993;**34**:604-10.
- Stell DA, Carter CR, Stewart I, *et al*. Prospective comparison of laparoscopy, ultrasonography and computed tomography in the staging of gastric cancer. *Br J Surg* 1996;**83**:1260-2.
- Adachi Y, Sakino I, Matsumata T, *et al*. Preoperative assessment of advanced gastric carcinoma using computed tomography. *Am J Gastroenterol* 1997;**92**:872-5.
- Watt I, Stewart I, Anderson D, *et al*. Laparoscopy, ultrasound and computed tomography in cancer of the oesophagus and gastric cardia: a prospective comparison for detecting intra-abdominal metastases. *Br J Surg* 1989;**76**:1036-9.
- Yeung HW, Macapinlac H, Karphe M, *et al*. Accuracy of FDG-PET in gastric cancer. Preliminary experience. *Clin Positron Imaging* 1998;**1**:213-21.
- Turlakow A, Yeung HW, Salmon AS, *et al*. Peritoneal carcinomatosis: role of (18)F-FDG PET. *J Nucl Med* 2003;**44**:1407-12.
- Walkey MM, Friedman AC, Sohtara P, *et al*. CT manifestations of peritoneal carcinomatosis. *AJR Am J Roentgenol* 1988;**150**:1035-41.
- Rösch T. Endosonographic staging of gastric cancer: a review of literature results. *Gastrointest Endosc Clin N Am* 1995;**5**:549-57.
- American Joint Committee on Cancer. *Cancer staging manual*, 5th edn., Philadelphia: Lippincott-Raven Press 1997.
- Catalano MF, Sivak MV Jr, Rice T, *et al*. Endosonographic features predictive of lymph node metastases. *Gastrointest Endosc* 1994;**40**:442-6.
- Canto M, Gislason G. Is extraluminal fluid (EFLUID) at endoscopic ultrasonography (EUS) as accurate marker of peritoneal carcinomatosis (PC)? A prospective study. *Gastrointest Endosc* 1998;**47**:AB142.
- Nguyen PT, Chang KJ. EUS in the detection of ascites and EUS-guided paracentesis. *Gastrointest Endosc* 2001;**54**:336-9.
- Branney SW, Wolfe RE, Moore EE, *et al*. Quantitative sensitivity of ultrasound in detecting free intraperitoneal fluid. *J Trauma* 1995;**39**:375-80.
- Gourtsoyiannis N, Daskalogiannaki M, Prassopoulos P. Imaging of the peritoneum, mesentery and omentum. In: Grainger RG, Allison D, Adam A, *et al*. In: *Grainger and Allison's diagnostic radiology: a textbook of medical imaging*, 4th edn. Edinburgh: Churchill Livingstone, 2001:1146.
- Forsby J, Henriksson L. Detectability of intraperitoneal fluid by ultrasonography and experimental investigation. *Acta Radiol Diagn* 1984;**25**:375-8.
- Nozoe T, Matsumata T, Sugimachi K. Usefulness of preoperative transvaginal ultrasonography for women with advanced gastric carcinoma. *Am J Gastroenterol* 1999;**94**:2509-12.
- Chen CH, Yang CC, Yeh YH. Preoperative staging of gastric cancer by endoscopic ultrasound: the prognostic usefulness of ascites detected by endoscopic ultrasound. *J Clin Gastroenterol* 2002;**35**:321-7.
- Chu KM, Kwok KF, Law S, *et al*. A prospective evaluation of catheter probe EUS for the detection of ascites in patients with gastric carcinoma. *Gastrointest Endosc* 2004;**59**:471-4.
- Lee YT, Ng EKW, Sung JY, *et al*. Ascites detected by endosonography in gastric cancer staging is predictive of peritoneal metastases. *Endoscopy* 2000;**32**:A23.
- Hayes N, Wayman J, Wadehra V, *et al*. Peritoneal cytology in the surgical evaluation of gastric carcinoma. *Br J Cancer* 1999;**79**:520-4.
- Suzuki T, Ochiai T, Hayashi H, *et al*. Importance of positive peritoneal lavage cytology findings in the stage grouping of gastric cancer. *Surg Today* 1999;**29**:111-15.
- Bando E, Yonemura Y, Takeshita Y, *et al*. Intraoperative lavage for cytological examination in 1,297 patients with gastric carcinoma. *Am J Surg* 1999;**178**:256-62.
- Cascinu S, Scartozzi M, Labianca R, *et al*. Italian Group for the Study of Digestive Tract Cancer (GISCAD). High curative resection rate with weekly cisplatin, 5-fluorouracil, epirubicin, 6S-leucovorin, glutathione, and filgrastim in patients with locally advanced, unresectable gastric cancer: a report from the Italian Group for the Study of Digestive Tract Cancer (GISCAD). *Br J Cancer* 2004;**90**:1521-5.
- Glehen O, Mohamed F, Gilly FN. Peritoneal carcinomatosis from digestive tract cancer: new management by cytoreductive surgery and intraperitoneal chemotherapy. *Lancet Oncol* 2004;**5**:219-28.
- Feussner H, Omote K, Fink U, *et al*. Pretherapeutic laparoscopic staging in advanced gastric carcinoma. *Endoscopy* 1999;**31**:342-7.
- Akahoshi K, Misawa T, Fujishima H, *et al*. Preoperative evaluation of gastric cancer by endoscopic ultrasound. *Gut* 1991;**32**:479-82.
- Ribeiro U, Gama-Rodrigues JJ, Bitelman B, *et al*. Value of peritoneal lavage cytology during laparoscopic staging of patients with gastric carcinoma. *Surg Laparosc Endosc* 1998;**8**:132-5.
- Lee YT, Hung CT, Wong WS, *et al*. Accuracy of endoscopic ultrasound in the diagnosis of hepatic malignant diseases. *Gastrointest Endosc* 2002;**56**:S131.