



## The safety and efficacy of combined phacoemulsification and trabeculectomy with releasable sutures

W J Stark, R K Goyal, O Awad, E Vito and A C Kouzis

*Br. J. Ophthalmol.* 2006;90:146-149  
doi:10.1136/bjo.2005.078212

---

Updated information and services can be found at:  
<http://bjournal.bmj.com/cgi/content/full/90/2/146>

---

*These include:*

### References

This article cites 17 articles, 4 of which can be accessed free at:  
<http://bjournal.bmj.com/cgi/content/full/90/2/146#BIBL>

### Rapid responses

You can respond to this article at:  
<http://bjournal.bmj.com/cgi/eletter-submit/90/2/146>

### Email alerting service

Receive free email alerts when new articles cite this article - sign up in the box at the top right corner of the article

---

### Topic collections

Articles on similar topics can be found in the following collections  
[Other ophthalmology](#) (2373 articles)

---

### Notes

---

To order reprints of this article go to:  
<http://www.bmjournals.com/cgi/reprintform>

To subscribe to *British Journal of Ophthalmology* go to:  
<http://www.bmjournals.com/subscriptions/>

## SCIENTIFIC REPORT

# The safety and efficacy of combined phacoemulsification and trabeculectomy with releasable sutures

W J Stark, R K Goyal, O Awad, E Vito, A C Kouzis

*Br J Ophthalmol* 2006;90:146–149. doi: 10.1136/bjo.2005.078212

**Aim:** To evaluate the combined phacoemulsification with acrylic intraocular lens implantation and trabeculectomy with releasable sutures, without the use of antimetabolites, performed by one surgeon.

**Methods:** A retrospective analysis was performed on 251 eyes of 198 patients after a combined phaco/trabeculectomy procedure, followed up for an average of 16 months for vision, intraocular pressure (IOP), and number of glaucoma medications. Cox proportional hazard regression analysis provided measures of relative risk (RR) or hazards ratios and 95% confidence intervals (CIs) associated with the occurrence of several conditions or complications of surgery.

**Results:** Mean preoperative variables were best corrected vision, 0.6 (SD 0.4) logMAR (20/80 Snellen); IOP, 18.7 (4.9) mmHg; and number of glaucoma medications, 1.7 (0.8). Mean postoperative results were best corrected vision, 0.2 (0.4) logMAR (20/32 Snellen); IOP, 15.1 (3.2) mmHg; and number of glaucoma medications, 0.3 (0.6). Postoperatively, the mean decreases from baseline were 19.2% for IOP and 84.1% for number of glaucoma medications; 85% of eyes required fewer glaucoma medications and 78% of eyes were medication free, with IOP control. There were no significant operative or postoperative complications.

**Conclusion:** Combined phacoemulsification and trabeculectomy with releasable sutures, in the absence of antimetabolites, is a safe, effective, and stable alternative for patients with cataracts and glaucoma.

The combined surgical treatment of glaucoma and cataracts has been the subject of some controversy. Recent advances in cataract incisional techniques and in glaucoma medications have changed the indications for surgery by minimising the severity of complications. In the early 1980s, extracapsular cataract extractions with trabeculectomy were reported to be effective, but larger wound size was associated with more inflammation and hyphaema.<sup>1–3</sup> In the 1990s, phacoemulsification and the use of small incision foldable lenses increased the success of combined phacoemulsification/trabeculectomy surgery (phaco/trabeculectomy). Early studies showed promising results.<sup>4</sup> Since techniques are changing rapidly, it is difficult to obtain well controlled data for combined procedures with more than 12 months of follow up. This study was initiated to evaluate the long term outcomes of combined phaco/trabeculectomies performed by one surgeon using a single technique.

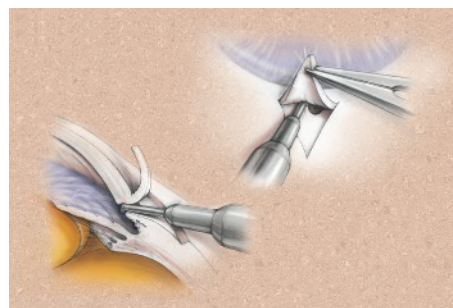
## PATIENTS AND METHODS

This retrospective study involved patients who had undergone a combined phacoemulsification with trabeculectomy by one surgeon (WJS) from 1997 to 2001. All patients in the

series had had a visually significant cataract and ophthalmological evidence of glaucomatous optic neuropathy, nerve fibre layer defects, and/or visual field loss despite medical therapy. The Johns Hopkins Medicine institutional review board reviewed this project and determined it qualified as exempt from review. Appropriate HIPAA regulations were followed.

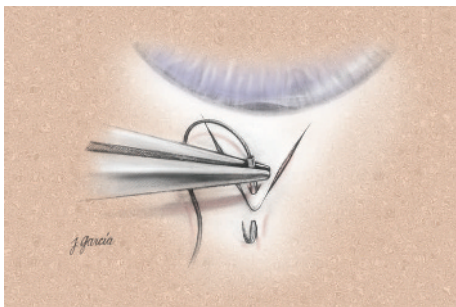
The preoperative data obtained for each patient included age, sex, ocular history, pre-existing medical conditions, type of glaucoma, visual acuity, IOP, eye operated on, and number of glaucoma medications. Postoperatively, visual acuity, IOP, number of glaucoma medications, and complications were documented.

Anaesthesia was achieved with a peri/retrobulbar block of 0.75% Marcaine and 2% lidocaine in a 50:50 mixture. The surgeon created a fornix based conjunctival flap and dissected a triangular half thickness scleral flap into a tunnel (fig 1); a sharp keratome was used to create a tunnel into the anterior chamber. No antimetabolites were used in these cases. After phacoemulsification, a foldable Acrysof MA60 (Alcon Laboratories, Inc, Fort Worth, TX, USA) lens was placed into the capsular bag. A sclerotomy was completed on the posterior lip of the tunnel with a Kelly Descemet's punch (Storz Instrument, Co Ref e2798), and a peripheral iridectomy performed with scissors (fig 1). The scleral flap was closed with one interrupted and two releasable 10-0 nylon sutures (Ethicon No 9000g, Ethicon Inc, Somerville, NJ, USA) (figs 2–7), and the conjunctiva closed with 10-0 Vicryl sutures (Ethicon No V4489). Topical steroids and antibiotics were applied. The patients were examined postoperatively, and the releasable sutures were removed at the slit lamp, as needed, to increase aqueous filtering through the trabeculectomy. The first releasable suture was usually removed at 5 days and the second suture at 12 days after surgery.

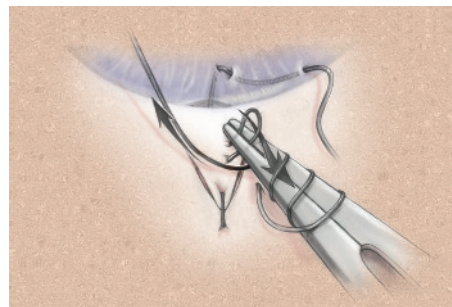


**Figure 1** Sclerotomy performed through a half thickness triangular scleral flap.

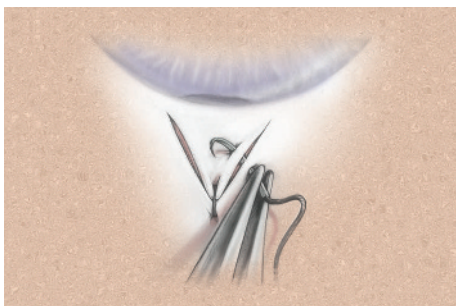
**Abbreviations:** BCVA, best corrected visual acuity; CI, confidence intervals; 5-FU, 5-fluorouracil; IOP, intraocular pressure; MMC, mitomycin C; RR, relative risk



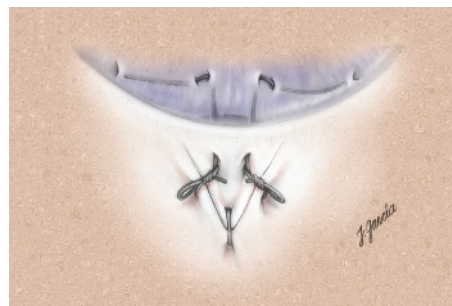
**Figure 2** Securing of scleral flap with one 10-0 nylon suture.



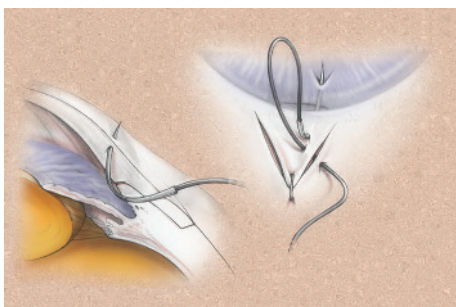
**Figure 6** The knot can be secured with three throws and pulled snug.



**Figure 3** Placement of releasable suture through scleral flap.



**Figure 7** Releasable sutures can be safely removed at the slit lamp.



**Figure 4** Suture should exit through clear cornea, with excess suture loop on the scleral flap.



**Figure 5** Leading edge of suture is buried in peripheral cornea for future ease of removal.

To evaluate outcome, we selected the independent variables of a decrease in IOP from the preoperative value and the risk of restarting postoperative glaucoma medications. The independent variables selected from the preoperative and postoperative database were: conjunctival scarring, diabetes,

hypertension, hyphaema, choroidal haemorrhages, and presence of a bleb. We used Cox proportional hazard regression analysis (Stata 7.0) for correlated data to ascertain the relative hazards or risks (RR) associated with a number of dependent variables.

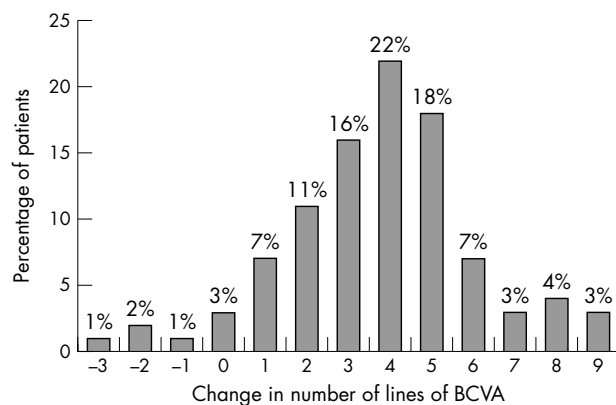
**RESULTS**

Combined phaco/trabeculectomy was performed on 251 eyes of 198 patients and followed up for a mean of 16 months (range 6–42 months). Forty eight per cent of the patients were male; average age was 76.5 (SD 10) years; 93% were white, 5% Middle Eastern, 1% African American, and 1% Asian.

Pre-existing medical conditions were hypertension (25.7%) and diabetes (8.1%). Pre-existing ocular conditions were age related macular degeneration (13.3%), Fuchs’ corneal dystrophy (8.6%), amblyopia (3.3%), epithelial basement membrane disease (2.8%), conjunctival scarring (1.4%), and epiretinal membrane (1.3%).

Types of glaucoma were primary open angle (68.6%), pseudoexfoliation (21.6%), narrow angle (11.4%), normal tension (4.3%), mixed mechanism (2.2%), traumatic (2.2%), uveitic (1.1%), and pigment dispersion (1.1%).

Postoperative variables included visual acuity, change in baseline IOP, and change in number of glaucoma medications. Best corrected visual acuity (BCVA) improved from a preoperative mean of 0.6 (0.4) logMAR (20/80 Snellen) to a postoperative mean of 0.2 (0.4) logMAR (20/32 Snellen). Ninety six per cent of eyes had improved postoperative visual acuity. Less than 3% of eyes lost two to three lines of spectacle BCVA (fig 8) because of progression of macular degeneration (five eyes) and diabetic retinopathy (two eyes). Mean preoperative IOP was 18.7 (4.9) mmHg and mean postoperative IOP was 15.1 (3.2) mmHg. Preoperatively, 51% of eyes required two or more medications (average 1.9 medications per eye); postoperatively, 85% of eyes required fewer glaucoma medications and 78% of eyes were medication free. Only 2% of eyes required more postoperative



**Figure 8** Results: visual acuity. Less than 3% of patients lost two or more lines of best corrected visual acuity.

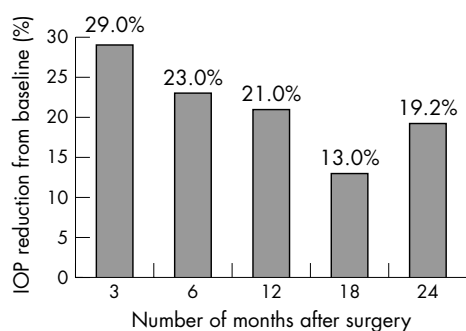
glaucoma medication for IOP control. The mean postoperative drop in IOP from baseline was 19.2% (fig 9), with a mean decrease in number of glaucoma medications of 84.1%. The percentage of eyes that were medication free or required fewer medications for IOP control remained constant at 85% over the 42 months of follow up.

Complications included temporary conjunctival wound leak (10.7% of eyes), transient choroidal detachment (7.5%), and transient circulating hyphaema (4%). All complications were transient and did not result in loss of spectacle BCVA.

The likelihood of restarting glaucoma medications was increased for many independent variables. Preoperative conjunctival scarring was associated with an eightfold (RR = 8.4; 95% CI = 2.0 to 36.0) greater likelihood of restarting medications. Also, the relative risk for patients with diabetes of restarting medications was greater than that for those without diabetes. The presence of a postoperative bleb increased the likelihood of a lower postoperative IOP (RR = 2.5; 95% CI = 1.56 to 3.91). A reduced likelihood of lower IOP was seen in cases with complications such as hyphaema (RR = 0.3; 95% CI = 0.13 to 0.37) and choroidal detachment (RR = 0.6; 95% CI = 0.34 to 0.99).

## DISCUSSION

Cataract surgery in patients with open angle glaucoma requires careful monitoring of postoperative pressure spikes; combined procedures can reduce the frequency and magnitude of this complication.<sup>5</sup> Many authors have outlined the indications for a combined procedure,<sup>6</sup> but no simple technique without the use of antimetabolites and with a low complication rate has been presented. Combined phaco/



**Figure 9** The average IOP reduction from baseline was 19.2%. Eighty five per cent of eyes required no (78%) or fewer (7%) glaucoma medications.

trabeculectomies should be scrutinised under three categories: (1) two site versus one site, (2) limbus based versus fornix based approach, and (3) use of antimetabolites.<sup>7</sup>

Several authors have reported no difference in IOP control between the one and two site approaches.<sup>8</sup> In combined phaco/trabeculectomy, limbus based and fornix based flaps were found to be equally effective in reducing IOP and improving vision, with no difference in postoperative complications or outcomes.<sup>9</sup> Our same site approach using a fornix based flap was successful in more than 85% of cases at last follow up (average of 16 months after surgery).

Over the past decade, antimetabolite agents such as 5-fluorouracil (5-FU) and mitomycin C (MMC) have been used in glaucoma surgeries to ensure functional success in bleb survival. However, many investigators have reported an increase in late onset bleb associated endophthalmitis since the advent of antimetabolite agents.<sup>10-12</sup> Other potential complications include postoperative hypotony, corneal erosions, endothelial toxicity, and wound instability.<sup>13 14</sup> With MMC, the overall incidence of bleb leaks and infections appears to be constant over time: 1.3% per year for endophthalmitis and 4.4% per year for any complication (bleb leak, blebitis, or endophthalmitis), which means that after 5 years, up to 23% of eyes may develop a complication.<sup>15</sup> Postoperatively, we saw no persistent bleb leaks or infections.

The combined phaco/trabeculectomy is a reasonably safe and effective procedure. Ninety six per cent of eyes in our series had improved visual acuity postoperatively. Less than 3% of patients lost two to three lines of BCVA (fig 8) all due to progression of age related macular degeneration or diabetic retinopathy. Fewer than 2% of patients required an increase in the number of glaucoma medications postoperatively. Complications were rare. Temporary leaks (10.7%) were manageable at office visits and were not persistent, except for one eye that required additional conjunctival sutures 3 weeks postoperatively. Choroidal detachments (7.5%) and hyphaemas (4%) were transient, and no eye developed infection or endophthalmitis.

The efficacy of a procedure is measured by the number of patients who achieve a desired result, and visual acuity improved postoperatively in 93% of eyes in our series. Preoperatively, 62% of patients had a BCVA of 20/60 or worse; postoperatively, 81% had a BCVA of 20/40 or better. Control of IOP was improved postoperatively. The mean drop in IOP from baseline was 19.2% (fig 9), and the mean drop in number of glaucoma medications was 84.1%. Seventy eight per cent of eyes were medication free at the time of last follow up.

Our analysis, however, showed that cumulatively the percentage of eyes that were medication free (78%) or required fewer (7%) glaucoma medications was 85% over a period of 42 months after surgery. Although our results were promising, the study population was primarily white people (94%), who usually have a lower risk of bleb failure than more heavily pigmented individuals. Thus, we conclude that antimetabolites may not be necessary for lower risk white patients who have not had previous ocular surgery.

Combining the cataract operation with the trabeculectomy offers the main advantage of requiring only one operation to achieve a lower IOP after cataract surgery. Lochhead *et al*<sup>16</sup> have reported that in elderly white patients with chronic open angle glaucoma, phaco-trabeculectomy is not as effective as trabeculectomy alone in reducing IOP. While this may be true it has not been documented in well controlled studies using modern phacoemulsification techniques. In addition, improved IOP control with fewer medications from the combined procedure may prevent further optic nerve damage in those patients with borderline control and in those patients who are not compliant in taking their medications.

Jampel *et al*<sup>17</sup> have recently performed an evidence based literature review of the effects of techniques on IOP after combined cataract and glaucoma surgery. Their conclusion based on the literature review was that the strongest evidence of efficacy exists for using (1) MMC, (2) separating the incisions for cataract and glaucoma surgery, and (3) removing the nucleus by phacoemulsification. We agree with point 3 but caution the indiscriminate use of MMC in lower risk white patients because of the higher complications of bleb leak and endophthalmitis. We personally have seen and believe that many of the successful MMC filters have significant bleb leaks that increase the potential for later complications. The decision for two site or one site surgery needs further evaluation. We prefer one site surgery and offer a word of caution for those using two site surgery. Self sealing corneal incisions can open when the eye becomes soft, leading to an ingress of periocular fluid into the eye. This might increase the risk of endophthalmitis. Therefore, for those using two site surgery, we recommend suturing the phacoemulsification wound.

In summary, our series of combined phaco/trabeculectomies resulted in excellent IOP control, substantial visual recovery, and a decrease in the number of glaucoma medications with few complications. This combined technique adds to our armamentarium a surgery that is reasonably safe, effective, predictable, and stable without the use of antimetabolites in lower risk white patients with glaucoma.

#### Authors' affiliations

W J Stark, R K Goyal, O Awad, E Vito, A C Kouzis, Wilmer Eye Institute, The Johns Hopkins University, School of Medicine, Baltimore, MD, USA

This work was supported in part by and Helen and Raymond Kwok Research Fund, and The Stavros Niarchos Foundation.

The authors have no proprietary interest in the devices mentioned here.

Correspondence to: Dr Walter J Stark, 600 N Wolfe Street, Maumenee 327, Baltimore, MD 21287, USA; [wstark@jhmi.edu](mailto:wstark@jhmi.edu)

Accepted for publication 2 October 2005

#### REFERENCES

- 1 **McCartney DL**, Memmen JE, Stark WJ, *et al*. The efficacy and safety of combined trabeculectomy, cataract extraction, and intraocular lens implantation. *Ophthalmology* 1988;**95**:754–63.
- 2 **Simmons ST**, Litoff D, Nichols DA. Extracapsular cataract extraction and posterior chamber intraocular lens implantation combined with trabeculectomy in patients with glaucoma. *Am J Ophthalmol* 1987;**104**:465–70.
- 3 **Skorpik C**, Gnad HD, Paroussis P. Trabeculectomy and intraocular lens implantation: a combined procedure. *J Cataract Refract Surg* 1987;**13**:39–42.
- 4 **Parker JS**, Stark WJ. Combined trabeculectomy, cataract extraction, and foldable lens implantation. *J Cataract Refract Surg* 1992;**18**:582–5.
- 5 **Krupin T**, Feitl ME, Bishop KI. Postoperative intraocular pressure rise in open-angle glaucoma patients after cataract or combined cataract filtration surgery. *Ophthalmology* 1989;**96**:579–84.
- 6 **Shields MB**. Combined cataract extraction and glaucoma surgery. *Ophthalmology* 1982;**89**:231–7.
- 7 **Casson RJ**, Salmon JF. Combined surgery in the treatment of patients with cataract and primary open-angle glaucoma. *J Cataract Refract Surg* 2001;**27**:1854–1863.
- 8 **Wyse T**, Meyer M, Ruderman JM, *et al*. Combined trabeculectomy and phacoemulsification: a one-site v two-site approach. *Am J Ophthalmol* 1998;**125**:334–9.
- 9 **Shingleton BJ**, Chaudhry IM. Phacotrabeculectomy: limbus-based versus fornix-based conjunctival flaps in fellow eyes. *Ophthalmology* 1999;**106**:1152–5.
- 10 **Jampel HD**, Quigley HA, Kerrigan-Baumrind LA, *et al*. Risk factors for late-onset infection following glaucoma filtration surgery. *Arch Ophthalmol* 2001;**119**:1001–9.
- 11 **Greenfield DS**, Suner UJ, Miller MP, *et al*. Endophthalmitis after filtering surgery with Mitomycin. *Arch Ophthalmol* 1996;**114**:943–9.
- 12 **Higginboham EJ**, Stevens RK, Musch DC, *et al*. Bleb-related endophthalmitis after trabeculectomy with mitomycin-C. *Ophthalmology* 1996;**103**:650–6.
- 13 **Joos KM**, Bueche MJ, Palmberg PF. One-year follow-up results of combined mitomycin C trabeculectomy and extracapsular cataract extraction. *Ophthalmology* 1995;**102**:76–83.
- 14 **Suner UJ**, Greenfield DS. Hypotony maculopathy after filtering surgery with mitomycin C. *Ophthalmology* 1997;**104**:207–15.
- 15 **DeBry PW**, Perkins TW, Heatley G. Incidence of late onset bleb related complications following trabeculectomy with mitomycin. *Arch Ophthalmol* 2002;**120**:297–300.
- 16 **Lochhead J**, Casson RJ, Salmon JF. Long term effect on intraocular pressure of phacotrabeculectomy compared to trabeculectomy. *Br J Ophthalmol* 2003;**87**:850–2.
- 17 **Jampel HD**, Friedman DS, Lubomski LH, *et al*. Effect of technique on intraocular pressure after combined cataract and glaucoma surgery: an evidence-based review. *Ophthalmology* 2002;**109**:2215–24.